



Hypoxic Ischemic Encephalopathy and Hypothermia

Hypoxic ischemic encephalopathy (HIE) is defined as an acute brain injury diagnosed by clinical and laboratory findings. HIE affects 6 in 1,000 live births in the United States (Zanelli, Stanley, & Kaufman, 2018). There are several causes of HIE in newborns, including interrupted circulation in the umbilical cord, abruption of the placenta or other insufficiencies of the placenta, maternal hypotension, and maternal hypoxia or difficulties during an infant’s resuscitation. HIE results in death for about 50% of infants impacted. Survivors may develop devastating complications that include mental retardation, epilepsy, and cerebral palsy.

There are several pathophysiologic mechanisms that cause the brain injury associated with HIE. The sympathetic nervous system is stimulated by asphyxia, which results in a redistribution of blood flow. Cardiac output is redistributed to the vital organs including the brain, heart, and lungs. Initially, systemic blood pressure increases to maintain cerebral blood flow, but with continued hypoxic insult, the neonate is unable to maintain adequate

cardiac output and cerebral perfusion is compromised. With continued hypoxic insult, the brain converts to anaerobic metabolism, resulting in an increase in lactic acid formation in the brain. The combination of energy failure, acidosis, free-radical formation, calcium accumulation, lipid peroxidation, and neurotoxicity from glutamate and nitric oxide disrupts the structure of the cell and ultimately result in cell death.

Approximately 6–15 hours after the initial event, a secondary reperfusion injury occurs. In this phase, there is a brief period of restored cellular function, followed by decreased cerebral blood flow and clinical deterioration due to increased calcium influx into the cell and continued cell injury. This phase involves irreversible cell death, either by necrosis or apoptosis.

Table 1 shows clinical findings associated with moderate and severe HIE.

Table 1. Moderate and Severe HIE

Category	Signs of HIE	
	<i>Moderate</i>	<i>Severe</i>
1. Level of consciousness	Lethargy	Stupor/coma
2. Spontaneous activity	Decreased activity	No activity
3. Posture	Distal flexion, complete extension	Decerebrate
4. Tone	Hypotonia (focal or general)	Flaccid
5. Reflexes		
–Suck	Weak	Absent
–Moro	Incomplete	Absent
6. Autonomic System		
–Pupils	Constricted	Deviation/dilated/non-reactive to light
–Heart rate		Variable
–Respiration	Bradycardia Periodic breathing	Apnea

From *The New England Journal of Medicine*, Seetha Shankaran, Abbot R. Laptook, Richard A. Ehrenkranz, et al, Whole-Body Hypothermia for Neonates with Hypoxic–Ischemic Encephalopathy, 353, 1574-1584. Copyright © 2005 Massachusetts Medical Society. Reprinted with permission from Massachusetts Medical Society.

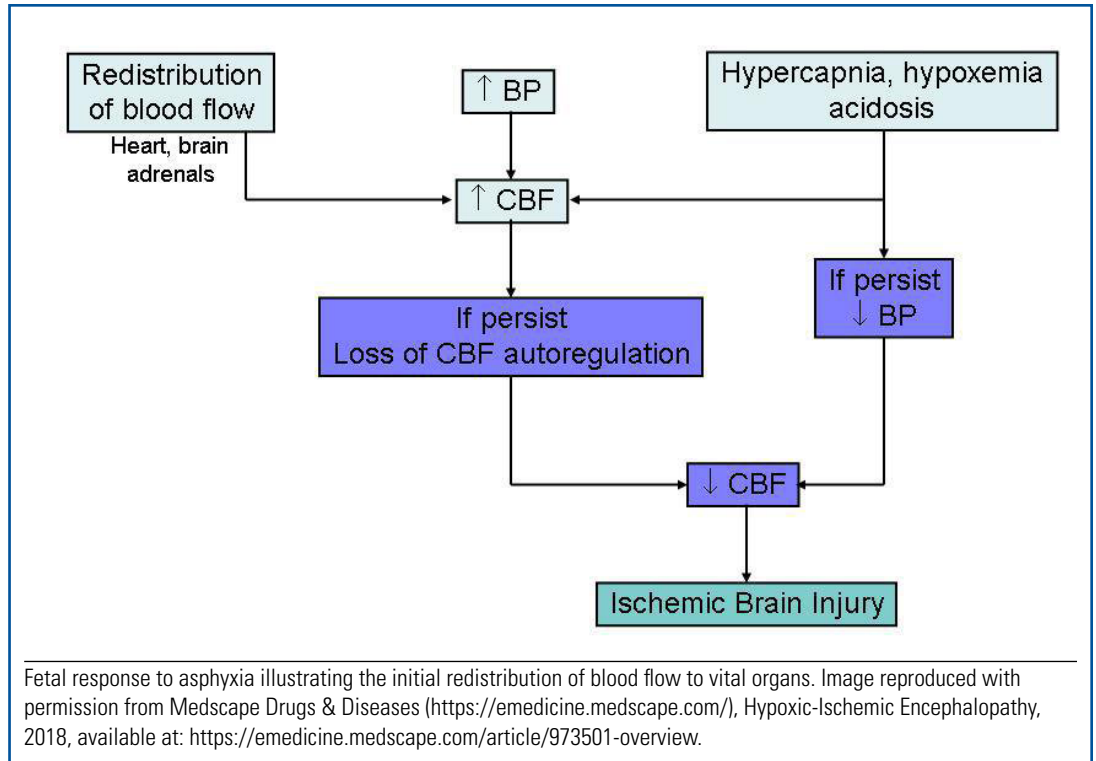


There is no treatment available for HIE; however, induced hypothermia is thought to provide neuroprotection to the brain and also may reduce the severity of the secondary reperfusion injury. The cerebral metabolic rate decreases by 6%–7% for every 1 °C decrease in body temperature. Induced hypothermia can be done via two interventions: head cooling or body cooling. Research has not yet shown which method is most effective. Currently, research has shown induced hypothermia should be used only on neonates older than 37 weeks gestational age at birth who have at least one of the following:

- a history of an acute perinatal event and are exhibiting signs of moderate to severe HIE
- a cord or neonatal pH less than 7.0
- base deficit greater than 16 on a cord gas or postnatal gas
- Apgar score less than 5 at 10 minutes.

In addition, treatment should begin within 6 hours of the injury to prevent a secondary reperfusion injury from occurring.

When caring for an infant with HIE, the most critical element of resuscitation is maintaining a stable airway and ensuring adequate circulation to prevent additional injury. These infants may exhibit seizures shortly after birth; therefore, an electroencephalogram to determine the presence of seizures and treatment with anticonvulsants often are required. Prior to induced hypothermia, infants often require mechanical ventilation and inotropic support to increase cardiac contractility. To initiate hypothermia treatment, the infant is placed on a precooled blanket per the



manufacturer's instructions. Ensure that all heat sources, such as the radiant warmer, are shut off. The infant's core temperature is monitored by an esophageal probe that is secured to the nose with tape; placement is verified with an X ray. The infant's body temperature is lowered to a range of 32.5 °C–34.5 °C. To prevent increased metabolic activity, sedatives and paralytics may be administered. Frequent evaluation of blood gases and electrolytes are critical for the management of these infants due to the many different complications of asphyxia. Nursing interventions when caring for the infant with induced hypothermia include clustering care to avoid excessive stimulation, decreasing light and noise in the immediate area, frequent skin assessments, and pain assessment and management.

Induced hypothermia continues for 72 hours after treatment begins, even if the infant's condition seems to improve. After 72 hours, the infant is rewarmed over a period of 6 hours by increasing the blanket temperature 0.5 °C every hour until 36.5 °C is reached. It is important for vital signs to be closely monitored because hypotension (secondary to vasodilation) may occur during rewarming. Once the infant is rewarmed, neurologic function will be assessed (physical exam, EEG, weaning of



anticonvulsants) to evaluate the effectiveness of the treatment. Parents should be educated on the possible long-term outcomes associated with HIE, including cerebral palsy, delayed neurodevelopment, and possible learning disorders.

Reference

Zanelli, S. A., Stanley, D. P., & Kaufman, D. A. (2018, January 11). *Hypoxic-ischemic encephalopathy*. Retrieved from <https://emedicine.medscape.com/article/973501-overview>

Bibliography

Nassef, S. K., Blennow, M., & Jirwe, M. (2012). Experiences of parents whose newborns undergo hypothermia treatment following perinatal asphyxia. *Journal of Obstetric, Gynecological and Neonatal Nursing, 42*(1), 38–47.



Hypoxic Ischemic Encephalopathy: Information for Parents

What is (HIE)?

Hypoxic ischemic encephalopathy (HIE) refers to a brain injury resulting from too little blood flow or oxygen delivery to the brain. It affects nearly 6 in 1,000 births per year in the United States.

What causes HIE?

There are many causes, but sometimes the exact cause can be unknown. Possible causes are too little oxygen supplied by the placenta during labor, a blockage in the baby's umbilical cord, a clot in the baby's brain, shock or sudden blood loss, or infection.

What are the symptoms of HIE?

Symptoms can include lethargy, weak-to-absent muscle activity, flaccid or "floppy" arms and legs, a weak or absent suck reflex, weak-to-absent breathing, seizures, and coma.

What is the treatment for HIE?

Treatment is meant to prevent any further damage due to low oxygen levels. Infants who are older than 36 weeks gestational age may qualify for treatment. Some babies may benefit from hypothermia, which is cooling of the head or the entire body, and is done by using a cooling blanket or cooling cap. Cooling limits the amount of damage to the brain after a low-oxygen event. The hypothermia treatment usually will last 72 hours, and the infant will be cooled to a temperature of 33.5 °C, or 92.3 °F; then the baby will slowly be rewarmed to a normal temperature.

Your baby may need to be sedated with medication. He or she is monitored for pain on a regular basis, and medication is given as needed. Due to the cooling and lack of movement by your baby, skin assessments will frequently be performed by your baby's provider. Optimal nutrition is important because of decreased blood flow to your baby's bowels. Total parenteral nutrition therapy may be started through an intravenous (IV) line so your baby can receive the nutrients he or she cannot get through eating.

How is HIE diagnosed?

Symptoms of HIE include

- history of an acute perinatal event
- an Apgar score of 5 or less at 10 minutes (Apgar scores are a simple way for your baby's provider to assess your baby's health right after being born.)
- continued need for ventilation initiated at birth and continued for at least 10 minutes
- low pH on blood in the umbilical cord
- level of alertness, ranging from being sluggish to being in a coma
- decreased or no spontaneous activity
- inappropriate posture, such as arching of back or neck; rotation of arms or legs
- weak or absent reflexes
- seizures
- constricted to nonreactive pupils
- decreased to absent breaths.

Electroencephalograms (EEG) often are performed after the infant has been rewarmed to evaluate the treatment and to look for seizures.

Not all babies with HIE will survive. Depending on the severity of the injury, some babies may have long-term problems.

Babies with moderate to severe HIE often have serious long-term problems, such as learning disorders, delayed development, or cerebral palsy. Follow up with a developmental specialist after discharge will be important to assess your baby's progress.